

# A rare case report of giant cell tumor of a tendon sheath

Ankit S Patel, Parth Thaker, Ruchir Patel, Mahesh Ladumore, Mukund M Prabhakar

Department of Orthopedics, BJ Medical College and Civil Hospital, Ahmedabad, Gujarat, India.  
Correspondence to: Ankit S Patel, E-mail: dr.ankit.p@gmail.com

Received August 19, 2015. Accepted September 9, 2015

## Abstract

Giant cell tumor of tendon sheath is a benign soft tissue lesion most commonly found in the flexor aspect of the hand and wrist. Being uncommon in the foot and ankle, the unusual appearance of this lesion can at times imitate other lesions such as lipoma, synovial sarcoma, malignant fibrous histiocytoma, synovial cyst, and ganglion. Thus, it is vital to include this lesion in differential diagnoses, especially if the lesion is found to be anchored to any of the surrounding tendons. This article describes the unusual occurrence of giant cell tumor of the tendon sheath of extensor digitorum brevis of great toe anchored to the capsule of metatarsophalangeal joint, which is rarely described in the literature.

**KEY WORDS:** Giant cell tumor, tendon sheath, extensor digitorum brevis, foot

## Introduction

Giant cell tumor of the tendon sheath (GCT-TS) is strongly associated with fibrous histiocytoma of synovium, pigmented nodular synovitis, teno-synovial giant cell tumor, localized nodular tenosynovitis, benign synovioma, and fibrous xanthoma of the synovium.<sup>[1-4]</sup> GCT-TS is adjudged the extra-articular equivalent of pigmented villonodular synovitis, emerging from the tendon sheaths, bursae, or ligaments.<sup>[5,6]</sup> The most frequent site of presentation is in the flexor region of the tendon sheath of fingers. Their notoriety in the foot is far less common. This article highlights the atypical occurrence of giant cell tumor along the extensor digitorum brevis tendon sheath.

## Case report

A 33-year-old lady presented with a swelling over the dorsal aspect of the great toe and the first web space, which was painless in nature and gradually increasing in size over

a period of 3 years. There was a history of blunt trauma at the onset. The patient showed a mild discomfort on walking, and during the later stages of enlargement showed difficulty in wearing the footwear. On examination, there was a 6×4 cm nontender bosselated firm swelling over the dorsal and medial aspects of the first toe and the adjoining web space. The skin over the swelling was pinchable. There was no free mobility of the swelling over the underlying bone. The X-ray showed a soft tissue lesion over the lateral aspect of the foot [Figure 1]. The patient possessed a report of fine-needle aspiration cytology of the swelling. It showed a moderately cellular smear with mononuclear cells, osteoclast-like multinucleate giant cells in a background of collagenous stromal fragments, chronic inflammatory cells, occasional foamy macrophages, and cholesterol clefts—the findings suggestive of giant cell tumor of tendon sheath. The patient was posted for excisional biopsy. Intraoperatively, a soft tissue mass was seen arising from the extensor digitorum brevis tendon sheath and the underlying capsule of the first metatarsophalangeal joint [Figure 2]. Following its excision, the adjoining areas of the first web space were curetted and treated with hydrogen peroxide, followed by a thorough wash with normal saline. The postoperative period was uneventful. The excisional biopsy showed a well-encapsulated tumor composed of mononuclear cells and osteoclast type of giant cells along with thick fibrous septa running through the tumor. Foamy cells, hemosiderin-laden macrophages, and cholesterol clefts were also seen—all the findings consistent with the diagnosis of giant cell tumor of tendon sheath [Figure 3].

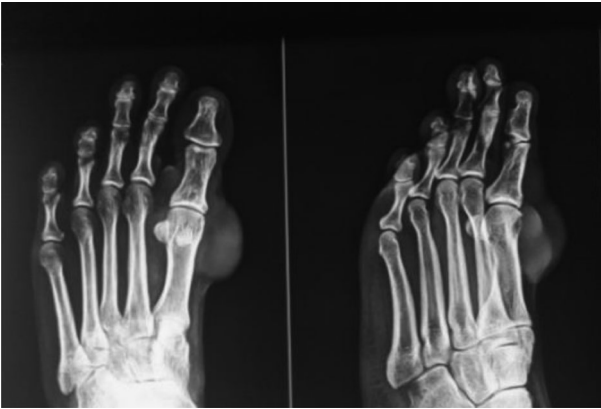### Access this article online

Website: <http://www.ijmsph.com>

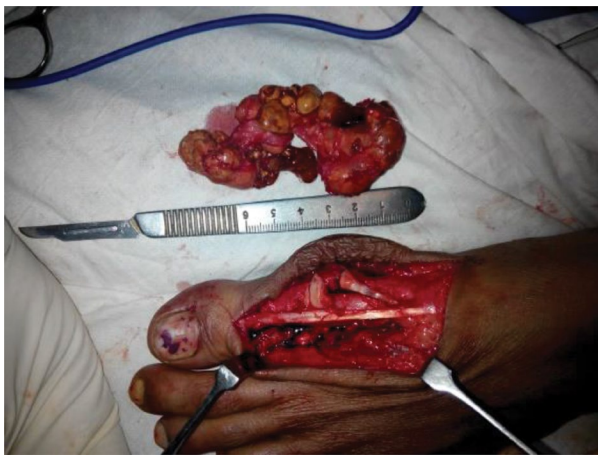DOI: 10.5455/ijmsph.2016.19082015114

Quick Response Code:

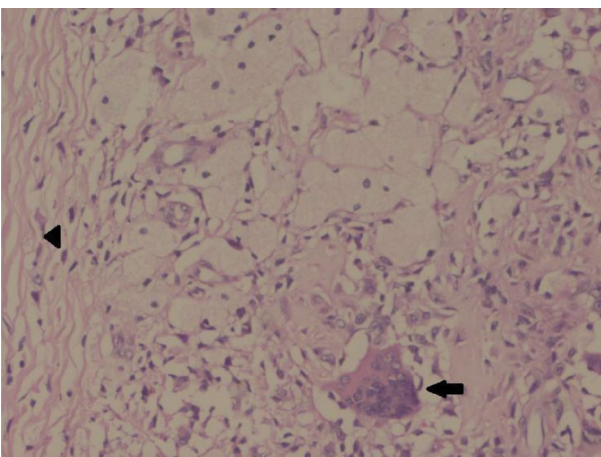




**Figure 1:** Perioperative X-ray film showing the soft tissue density overlying the first metatarsophalangeal joint.



**Figure 2:** Intraoperative picture showing the origin from tendon sheath of extensor digitorum brevis and capsule of first metatarsophalangeal joint.



**Figure 3:** (Microscopic 400X) Magnification view showing multinucleated osteoclast giant cell (black arrow), spindle-shaped mesenchymal cells and tendon sheath (arrow head).

## Discussion

Giant cell tumor of tendon sheath is a slowly growing benign mesenchymal tumor arising from the synovial membrane. Their nature is unclear in whether these lesions represent reactive lesions or true neoplasm.<sup>[7]</sup> These lesions usually present in the third to fifth decades with a slight female predilection. The most common site of occurrence is the hand and wrist, especially the flexor tendon sheath of fingers. Although the ankle and foot constitute the next common site after the hand and wrist, it is rare when compared with the upper limb lesions.<sup>[4]</sup> To the best of our knowledge, till date, there has been no reported case of giant cell tumor arising from the extensor digitorum brevis tendon sheath.<sup>[8]</sup> The most common presenting clinical feature is a slowly growing painless mass of long duration, as seen in our case. The X-rays might show soft tissue densities with or without adjacent bony cortical erosions. Ultrasonography shows solid homogeneous hypoechoic mass. Magnetic resonance imaging (MRI) helps in differentiating the giant cell tumor of tendon sheath from other soft tissue lesions such as lipoma, synovial sarcoma, malignant fibrous histiocytoma, synovial cyst, and ganglion, all of which constitute the differential diagnosis of the former. The MRI features of giant cell tumor of tendon sheath are highly characteristic. T1 weighted image reveals lesions to be isointense or hypointense to that of the muscle and hypointense on T2 weighted images.<sup>[9]</sup> The characteristic low signal on T1 and T2 weighted images is attributed to the paramagnetic effect of hemosiderin and the abundant collagenous stroma.<sup>[10]</sup> Heterogeneous signal intensity may occur depending on the histological composition. The gross pathological features include a well-circumscribed lobulated or multinodular encapsulated mass with varying degrees of hyalinization. On microscopy, the cellular infiltrate is constituted by macrophage-like mononuclear cells, epithelioid histiocyte-like cells, osteoclast-like giant cells, and xanthomatous cells.<sup>[1]</sup> Hemosiderin-laden macrophages and cholesterol clefts are also seen. Treatment is by marginal excision. The most bothering fact to the surgeon is the high rate of local recurrence of up to 45%, after excision.<sup>[11]</sup> Complete removal of the affected tissue is of utmost importance in preventing recurrence. Careful meticulous dissection and use of magnification devices aids in achieving this goal. Osseous involvement, radiologically evidenced by the presence of bony erosions, is a risk factor for local recurrence.<sup>[12]</sup> There has been no description in literature regarding the usage of any local adjuvants, after tumor excision, for preventing recurrence. In our case, after the complete local excision of the tumor, we have thoroughly curetted the adjoining bony surfaces and treated them with hydrogen peroxide, followed by a saline lavage. Hydrogen peroxide serves as a mode of chemical cauterization and, thus, helps in eliminating microscopic tumor remnants if any left over after excision. Postoperative radiotherapy may have a role in the cases in which complete excision may not be possible.<sup>[11]</sup> Regular follow-up is a must in all the cases after excision to identify recurrences, if any.

## Conclusion

Giant cell tumor of tendon sheath must be considered as a differential diagnosis of a soft tissue lesion in the foot, even though it is rare. The idea of usage of adjuvants in the context of preventing recurrence sounds promising. Nevertheless, it needs to be worked on in the future to know its true efficacy.

## References

1. Monaghan H, Salter D, Al-Nafussi A. Giant cell tumour of tendon sheath (localised nodular tenosynovitis): clinicopathological features of 71 cases. *J Clin Pathol* 2001;54(5):404–7.
2. Martin RC II, Osborne DL, Edwards MJ, Wrightson W, McMasters KM. Giant cell tumor of tendon sheath, tenosynovial giant cell tumor, and pigmented villonodular synovitis: defining the presentation, surgical therapy and recurrence. *Oncol Rep* 2000;7(2):413–9.
3. Coster AA. Giant cell tumor of tendon sheath (benign synovium). *J Am Podiatry Assoc* 1976;66(7):538–41.
4. Jones FE, Soule EH, Coventry MB. Fibrous xanthoma of synovium (giant-cell tumor of tendon sheath, pigmented nodular synovitis). A study of one hundred and eighteen cases. *J Bone Joint Surg Am* 1969;51(1):76–86.
5. Waldt S, Rechl H, Rummeny EJ, Woertler K. Imaging of benign and malignant soft tissue masses of the foot. *Eur Radiol* 2003;13(5):1125–36.
6. Llauger J, Palmer J, Monill JM, Franquet T, Baqué S, Rosón N. MR imaging of benign soft-tissue masses of the foot and ankle. *Radiographics* 1998;18(6):1481–98.
7. Vogrincic GS, O'Connell JX, Gilks CB. Giant cell tumor of tendon sheath is a polyclonal cellular proliferation. *Hum Pathol* 1997;28(7):815–9.
8. Ly JQ, Carlson CL, LaGatta LM, Beall DP. Giant cell tumor of the peroneus tendon sheath. *AJR Am J Roentgenol* 2003;180(5):1442.
9. De Beuckeleer L, De Schepper A, De Belder F, Van Goethem J, Marques MC, Broeckx J, et al. Magnetic resonance imaging of localized giant cell tumour of the tendon sheath (MRI of localized GCTTS). *Eur Radiol* 1997;7(2):198–201.
10. Jelinek JS, Kransdorf MJ, Shmookler BM, Aboulaia AA, Malawer MM. Giant cell tumor of the tendon sheath: MR findings in nine cases. *AJR Am J Roentgenol* 1994;162(4):919–22.
11. Kotwal PP, Gupta V, Malhotra R. Giant-cell tumour of the tendon sheath. Is radiotherapy indicated to prevent recurrence after surgery? *J Bone Joint Surg Br* 2000;82(4):571–3.
12. Reilly KE, Stern PJ, Dale JA. Recurrent giant cell tumors of the tendon sheath. *J Hand Surg Am* 1999;24(6):1298–302.

**How to cite this article:** Patel AS, Thaker P, Patel R, Ladumore M, Prabhakar MM. A rare case report of giant cell tumor of a tendon sheath. *Int J Med Sci Public Health* 2016;5:829-831

**Source of Support:** Nil, **Conflict of Interest:** None declared.